

**TREATMENT OF SCIATICA WITH MUSCLE WEAKNESS
WITH FLEXION DISTRACTION AND EXTENSION EXERCISES**

December 21, 2006

Donna Lieberman, DC

BACK TO HEALTH CHIROPRACTIC

Cortland, NY

NOTES OF INTEREST IN THIS CASE:

1. This is a free fragment sequestered disc at L5-S1 into the left paracentral vertebral canal contacting the cauda equina and left S1 nerve root. It had been treated with physical therapy and medical drug treatment prior to chiropractic intervention.
2. This patient had a history of low back pain which evolved to only left leg pain with no back pain. This is classic for a free fragment.
3. Dysuria was present indicating the cauda equina compression.
4. This patient was referred to Dr. Lieberman by the medical doctor treating the patient.
5. Previous care had been pain relievers, physical therapy McKenzie treatment.
6. Motor weakness of the left gastrocnemius muscle was found at 2/5, Achille's reflex diminished, hypesthesia of the left S1 dermatome. SLR positive at 20 degrees and hyperextension of the lumbar spine caused low back pain.
7. 16 flexion distraction adjustments over 12 weeks yielded 80% pain relief, improvement of motor power. Chondroitin sulfate was taken. A neurosurgical evaluation during care resulted in the suggestion to continue chiropractic care.

QUESTION: DO YOU THINK THIS TYPE CASE RESULTS IN EXCELLENT RESPECT, RAPPORT AND REFERRAL WITH OTHER TYPES OF HEALING ARTS PRACTITIONERS? OF COURSE THE ANSWER IS YES. I LOOK FORWARD TO STUDYING WITH YOU IN THE FUTURE.

THANK YOU, DONNA LIEBERMAN, D.C., FOR SHARING THIS RECERTIFICATION CASE WITH US. WE LEARNED A GREAT DEAL ABOUT A DISC CONDITION THAT UP TO RECENT YEARS WOULD HAVE WENT TO SURGERY.

Sincerely,

James M. Cox, D.C., D.A.C.B.R.

PRESENTATION AND EXAMINATION FINDINGS

32 year old Caucasian female presented to our office on 09-19-06 as a new patient with chief complaints of low back pain and left leg pain extending to her foot.

HISTORY

She was examined at the request of her Medical Doctor/ Physician's Assistant due to on-going disc and myelopathy symptoms. The patient stated she had a history of lower back pain with her 3 pregnancies. She is a married homemaker and mother of 3 children, ages 2, 4 and 6. She is a non-smoker and runs 2-3 miles per day for exercise. She reports having some lower back pain in the weeks prior, but on 08-25-06 her pain increased and traveled into her left foot. Over time her lower back pain released, but the pain in her left thigh and foot increased and became constant. Initially she did have some numbness which she described as "numbness in the pelvis" but that sensation had resolved prior to seeking treatment at this office. She denied a loss of bowel or bladder control, but she did report dysuria as "urination had become painful with the lower back pain and sciatica".

Prior to her initial chiropractic consultation and care, the patient was evaluated by her Physician's Assistant who obtained an MRI of her lumbar spine on 09-07-06. Medication management prescribed Hydrocodone, Skelaxen and Naprosen. She was referred to and treated by a physical therapist. She experienced some mild short term relief with McKenzie prone lumbar extension and electrical stimulation during the physical therapy care. The patient reported sitting, driving, lifting, pushing and bending increased her symptoms while lying down; moist heat and prescription medication relieved them. She was asked to grade her complaints on a scale of 0 absent to 10 excruciating. She graded her left lower extremity pain a constantly present, moderately annoying 3/10 and reported the sciatica had affected her sleep. The initial Back Index score was 26/50= 52%.

REVIEW OF MEDICAL RECORDS

Medical records from physical therapist revealed treatment prior to this chiropractic consultation consisted of McKenzie prone lumbar extension exercises and electrical stimulation to her lumbar paraspinal muscles.

IMAGING

No x-rays were taken. However, lumbar MRI was taken on 09-07-06. The report stated "medium sized, left sided central disc protrusion noted at L5-S1. There is a large disc extrusion at L5-S1 into the left lateral recess. Disc bulging at L4-5 and central canal stenosis at L5-S1". Study the following MRI study and the read of each. This is a very large free fragment.

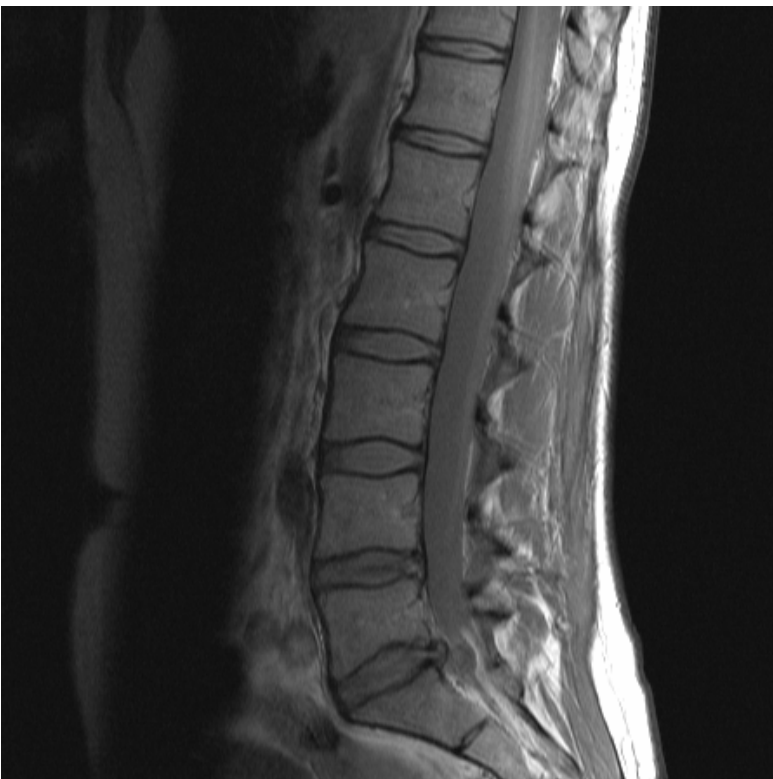

Figure 1. On this T2 weighted sagittal image, note the large free fragment of L5-S1 nuclear material lying within the vertebral canal and extending posteriorly to the lamina-spinous process junction.

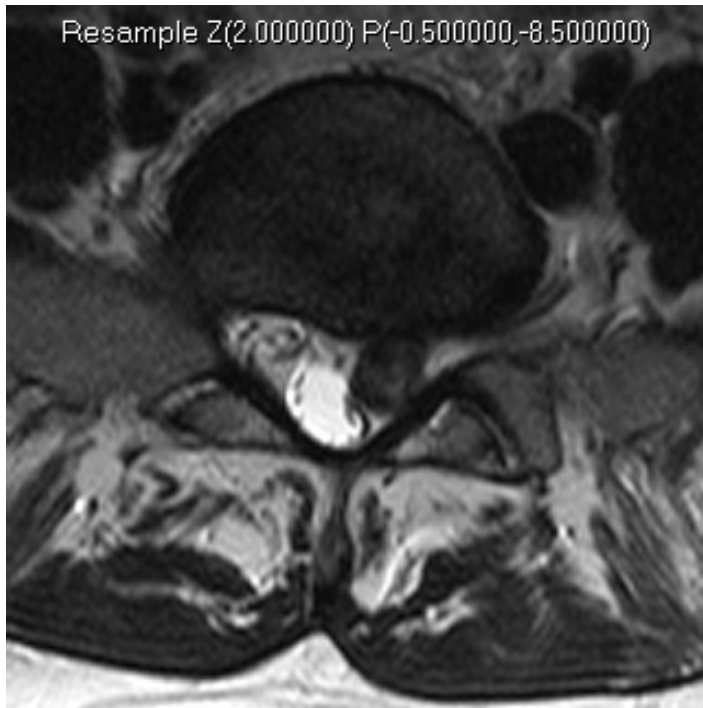


Figure 2. This T2 weighted axial image shows the large left paracentral free fragment sequestration of the L5-S1 disc extending posterior to the spinous process-lamina junction and displacing the cauda equina right of center.

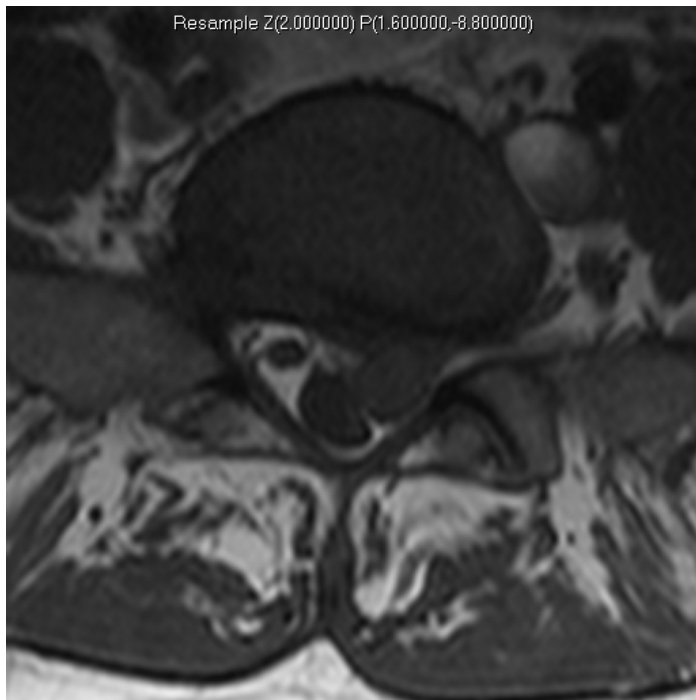


Figure 3. This is the T1 weighted image of Figure 2 with the same findings.

PHYSICAL EXAMINATION

Initial examination on 09-19-06 revealed the patient's height at 5'4" and weight at 129 lbs. Pulses of her lower extremities were present and equal bilaterally. Antalgic posture in right lateral bending with flattened lumbar lordosis was present. Observation revealed visible and palpable muscle hypertonicity in her lumbar paraspinal musculature. She moved about with apparent distress. The patient exhibited Minor's sign when attempting to rise from the seated position. Palpation revealed active trigger points in her lumbar paraspinal and gluteal musculature. Motion palpation revealed hypo-mobile motor units in her middle and lower lumbar spine. Heel and toe walk were performed. Heel walk was painful but graded 5/5 muscle strength. The patient was unable to perform toe walk due to pain and muscle weakness on her left. Left toe walk was graded 1/5 muscle strength. Muscle strength of her left gastrocnemius was graded 2/5 while supine. Goniometric measurements of lumbar range of motion revealed lumbar ROM was restricted in all planes but lumbar extension lessened her left lower extremity pain. McKenzie repetitive motion testing evaluation revealed prone lumbar extensions did lessen the intensity of her foot pain. The numbness in her left foot was unchanged with this testing. Extremity reflexes were graded +2 with the exception of the left Achilles reflex which was graded +1. Babinski was down going and there was no evidence of ankle clonus. Wartenberg neurologic pinwheel revealed a hypoesthesia over her posterior left leg into the lateral foot. There was no apparent discrepancy in the circumference of her lower extremities. Patient passed tolerance testing for Flexion Distraction to her lumbar spine. (2)

Sneezing was reported to cause lower back and buttock pain, but she denied a loss of bowel or bladder function. Hyperextension caused left lower back pain. Straight leg raise was positive on her left at 20° elevation, and she reported her left foot numbness was increased. (1) The Well Leg Raise was negative.

DIAGNOSIS

722.73 Left large L5-S1 sequestered disc fragment

724.02 L5-S1 lumbar spinal stenosis

TREATMENT

The patient was provided information about her condition and its possible outcomes and risks. She signed an Informed Consent Form for initiation of treatment. The treatment plan consisted of Flexion Distraction to her lumbar spine via Cox Technic Protocol, McKenzie prone lumbar extensions, electric muscle stimulation and use of cold packs. On her first visit she was treated with Cox® Technic Protocol 1 only. (2) On her 3rd visit she reported her lower extremity pain was less intense but still had pain into her left foot. Cox Technic Protocol 2 was added to her treatment plan with circumduction. (2) She was under concurrent care with her medical doctor with oral steroids in addition to the medications listed above. The patient's home therapy included instructions to perform McKenzie prone lumbar extensions 10x/ hour unless peripheralization of her sciatica occurred. The frequency of her home exercise program was reduced to twice per day as her condition improved. She was instructed to use cold packs and moist heat packs over her lumbar paraspinal and left gluteal areas, to avoid sitting, and to walk for exercise. As she responded to treatment, her care was expanded to include gentle osseous adjustments to her thoracic and lumbar spine. This patient was instructed in core stabilization exercises (quadrupeds, crunches, oblique crunches, squats, lunges and bridges).

REEXAMINATION FINDINGS

Re-exam after on 12-19-2006 revealed the circumferences of her legs was within normal limits at 13 1/4" on her right and 13 3/4" on her left. Toe walk was still weak compared to her right but was graded 3/5 as it was somewhat improved from her initial visit. Patient was treated 16 times from 09-19-06 till her most recent visit on 12-19-06. Patient estimated to feel approximately 80% improved overall. Back Index score on 11-21-06 was 11/50=22%. This was improved from her initial office visit score of 26/50=52%. Her thigh and foot pain are now intermittent and very mild. She estimated her lower extremity pain was present less than 50% of her day. The lateral foot numbness is still constant but significantly less intense. She graded the numbness in her foot a mild 1-2/10. She feels the numbness is gradually diminishing. Re-examination revealed patient is able to heel and toe walk and she can elevate herself up against gravity standing only on her left foot 6 times before feeling fatigued in her left ankle. Patient is currently being treated with Flexion Distraction twice per month. She continues to perform prone lumbar extensions and core stabilization exercises at home, she is walking 2-3 miles per day and using moist heat to lessen her pain and speed healing. In addition, she has been recommended to take 1500mg of glucosamine and chondroitin sulfate daily. During her care she had a consultation with a neurosurgeon. Since her muscle weakness was improving he advised against surgery and he recommended she continue with both the chiropractic and physical therapy. He suggested the patient follow up with him only if her condition deteriorated. The patient has since discontinued physical therapy and all of her prescription and over the counter medications.

CONCLUSION AND DISCUSSION

The examination of this patient revealed good information on which to base the diagnosis. Since the patient already had an MRI prior to the examination, its showing the herniation and stenosis correlated with the physical examination findings. Karppinen reported that the degree of displacement on MRI did not correlate with subjective symptoms, however, a correlation was associated with straight leg raising: pain for herniation, no pain for non-herniation. (1) As Modic reported as well, there is no correlation between the size of the disc herniation and the disability it causes.

This patient was interesting as she did well with a combination of therapies: exercise and flexion-distraction. (4, 5) Her in-office treatment consisted of Cox® Flexion Distraction, Protocol 1 to start then Protocol 2 once 50% relief of her pain abated (2), and her home exercise regime was primarily of repetitive prone lumbar extensions (McKenzie Exercises). This patient's large disc herniation at L5-S1 responded well to flexion-distraction which helped reduce the inflammation process and increase the nutrition flow (6) and further opened the canal space and reduced the pressure on the nerve (7). Despite the large size of the herniation, her response to conservative care was positive. (3, 8)

REFERENCES

1. Karppinen J. et al. Severity of Symptoms and Signs in Relation to MRI Findings Among Sciatic Patients. *Spine* 2001; 26 (7): E149-E154
2. Cox JM: *Low Back Pain: Mechanism, Diagnosis, Treatment*, 6th edition. Baltimore: Lippincott Williams & Wilkins, 1999: chapter 9.
3. Komori H: Contrast enhanced MRI in conservative management of lumbar disc herniation. *Spine* 1998;23(1)
4. Cambron JA, Gudavalli MR, Hedeker D: et al: One year follow up of a randomized clinical trial comparing flexion distraction with an exercise program for chronic low back pain. *J Altern Complementary Med* 2006;Sept.:12(7):659-68
5. Cambron JA, Gudavalli M, McGregor M, et al: Amount of health care and self care following a randomized clinical trial comparing flexion-distraction with exercise program for chronic low back pain: *Chiropractic and Osteopathy* 2006;14:19
6. Guehring, Thorsten MD*; Omlor, Georg W. MD*; Lorenz, Helga DVM*; Engelleiter, Karl MD*; Richter, Wiltrud PhD*; Carstens, Claus MD*; Kroeber, Markus MD: Disc Distraction Shows Evidence of Regenerative Potential in Degenerated Intervertebral Discs as Evaluated by Protein Expression, Magnetic Resonance Imaging, and Messenger Ribonucleic Acid Expression Analysis *Spine* 2006;31(15): 1658-1665
7. Gudavalli MR: Estimation of dimensional changes in the lumbar intervertebral foramen of lumbar spine during flexion distraction procedure. *Proceedings of the 1994 International Conference on Spinal Manipulation*, June 10-11, 1994, Palm Springs, CA, pp 81.
8. Modic MT: Contrast-Enlarged MRI In Acute Lumbar Radiculopathy A Pilot Study of the Natural History. *Neuroradiology* 1995;195